



















Systematic Review

Orthodontic Surgical Treatment of Impacted Mandibular Canines: Systematic Review and Case Report

Alessio Danilo Inchingolo ^{1,†}, Vincenzo Carpentiere ^{1,†}, Fabio Piras ¹, Anna Netti ¹, Irene Ferrara ¹, Mariagrazia Campanelli ¹, Giulia Latini ¹, Fabio Viapiano ¹, Stefania Costa ¹, Giuseppina Malcangi ¹, Assunta Patano ¹, Sabino Ceci ¹, Antonio Mancini ¹, Carlo Lucia ¹, Antonio Scarano ², Felice Lorusso ², Andrea Palermo ³, Anna Maria Ciocia ¹, Francesco Inchingolo ^{1,*}, Biagio Rapone ^{1,*}, Angelo Michele Inchingolo ^{1,‡}, Daniela Di Venere ^{1,‡} and Gianna Dipalma ^{1,‡}

¹ Department of Interdisciplinary Medicine, University of Bari "Aldo Moro", 70124 Bari, Italy

² Department of Innovative Technologies in Medicine and Dentistry, University of Chieti-Pescara, 66100 Chieti, Italy

³ Implant Dentistry College of Medicine and Dentistry Birmingham, University of Birmingham, Birmingham B46BN, UK

* Correspondence: francesco.inchingolo@uniba.it (F.I.); biagiorapone79@gmail.com (B.R.); Tel.: +39-3312111104 (F.I.); +39-3477619817 (B.R.)

† These authors contributed equally to this work as co-first Authors.

‡ These authors contributed equally to this work as co-last Authors.



Citation: Inchingolo, A.D.; Carpentiere, V.; Piras, F.; Netti, A.; Ferrara, I.; Campanelli, M.; Latini, G.; Viapiano, F.; Costa, S.; Malcangi, G.; et al. Orthodontic Surgical Treatment of Impacted Mandibular Canines: Systematic Review and Case Report. *Appl. Sci.* **2022**, *12*, 8008. <https://doi.org/10.3390/app12168008>

Academic Editors:

Domenico Ciavarella, Angela Pia Cazzolla, Nunzio Francesco Testa and Michele Di Cosola

Received: 24 July 2022

Accepted: 9 August 2022

Published: 10 August 2022

Publisher's Note: MDPI stays neutral with regard to jurisdictional claims in published maps and institutional affiliations.



Copyright: © 2022 by the authors. Licensee MDPI, Basel, Switzerland. This article is an open access article distributed under the terms and conditions of the Creative Commons Attribution (CC BY) license (<https://creativecommons.org/licenses/by/4.0/>).

Abstract: Background: In the literature, there are few studies on included mandibular canines and possible therapeutic solutions for arch restoration. The aim of this review was to evaluate how the recovery of included mandibular canines is performed in adolescent patients with mixed or permanent dentition. The clinical case reported is that of successful orthodontic surgical treatment in an 11-year-old mixed-dentition patient with an included mandibular right canine. Methods: A literature search was performed using the PubMed/Medline, Scopus, Web of Science, and Cochrane Library databases with the following Boolean indicators: canine, mandibular, impacted. The inclusion criteria were year of publication between 2017 and 2022, orthodontic canine surgical approach included, age between 9 and 18 years, free full text, and English language. Results: A total of 536 articles was identified through the electronic search, and 11 articles published between 2017 and 2022 were ultimately included in the qualitative analysis. Conclusions: In the majority of cases, combined surgical–orthodontic therapy, as reported in the studies that we reviewed, is successful in correcting the eruption defect, restoring the canine to occlusion and the physiological arch perimeter, and maintaining the health of the periodontal supporting tissues.

Keywords: included mandibular canines; transmigrated mandibular canines; orthodontic extrusion; malocclusion

1. Introduction

Altered tooth eruption indicates a tooth that fails to achieve the correct position in the arch, and can result in two clinical conditions that can be combined: inclusion, and transmigration. The incidence of included mandibular canines (IMCs) and transmigrated mandibular canines (TMCs) is rare, and is less frequent than that of impacted maxillary canines (IMXCs) [1]. IMCs have a prevalence of 0.05% to 0.4%, while IMXCs have a frequency of inclusion ranging from 1 to 3% [2].

The included tooth may occasionally remain in the same hemiarch or migrate laterally via a phenomenon called transmigration [3]. The mandibular and maxillary canines play a fundamental role in maintaining the arch form and function. Failure of included canines to recover may result in resorption or migration of near roots, loss of natural arch form, or the formation of dentigerous cysts [4].

According to Mupparapu's classification (Figure 1), TMCs are classified into five types [5]; type 1 is the most frequent. Early diagnosis makes it possible to assess the extent of canine transmigration and reduce aesthetic and functional complications [6–10].

MUPPARAPU CLASSIFICATION OF CANINES TRANSMIGRATION

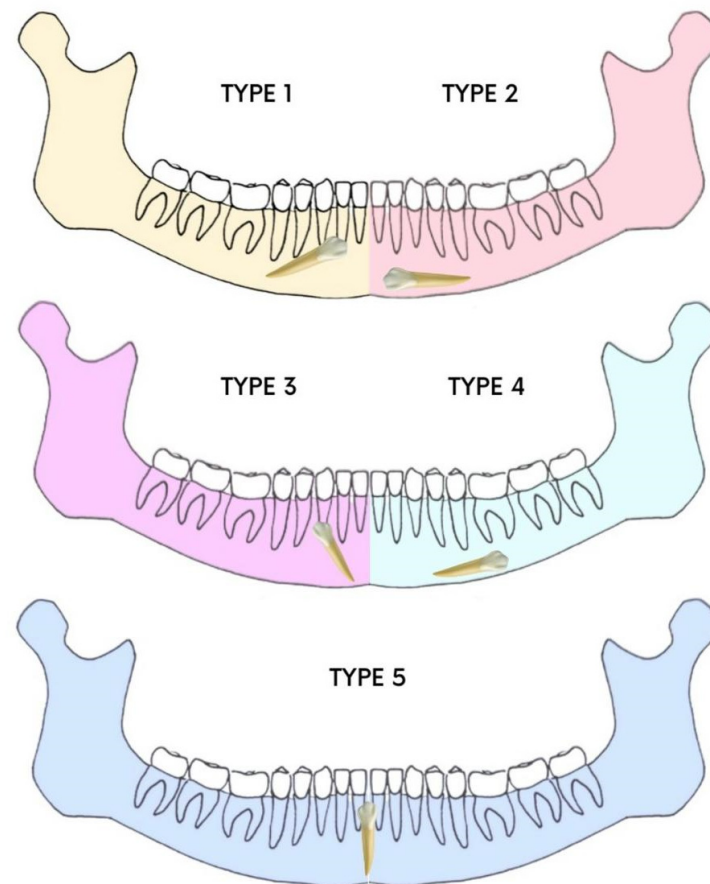


Figure 1. Mupparapu classification.

There are some hypotheses as to the causes of included mandibular canines, and these include premature loss of deciduous teeth, retention of the deciduous canine, odontomas, crowding, and supernumerary teeth [11,12]. However, the etiology and exact mechanism are still unclear [12]. Consequently, it is difficult to find clinical guidelines derived from valid studies based on large patient samples. The current state of the art provides for various approaches to the problem of included canines. Depending on the age of the patient and the severity of the inclusion, interceptive therapy is provided where possible; guided forced eruption with repositioning in the arch is implemented in cases of medium severity; and in severe cases that cannot be recuperated, avulsion of the element is performed [13]. Early diagnosis and clinical and radiological evaluation can help the dentist to plan the surgical technique and avoid possible complications [14]. Surgical techniques provide for guided eruption with a closed or open technique in the case of buccal positioning of the included tooth [15,16]. Few systematic reviews on this subject can be found in the literature; therefore, it is difficult for clinicians to identify clear guidelines on the topic [17]. The aim of this article is to describe the buccal surgical approach used to engage and return the mandibular canine to the arch, and to review the scientific literature regarding the recurrence of IMCs, the successes described, the periodontal health of the treated tooth, and the techniques adopted.

2. Materials and Methods

2.1. Systematic Literature Review Methodology

2.1.1. Search Strategies

Article screening was performed in accordance with the PRISMA (Preferred Reporting Items for Systematic Reviews and Meta-Analyses) guidelines [18]. The review protocol was registered with PROSPERO under the unique number CRD42022342607. Details of the protocol can be found at <https://www.crd.york.ac.uk/prospero> (accessed on 8 July 2022).

The search strategy was conducted with the keywords ((canine) AND (mandibular)) AND (impacted) as illustrated in Table 1.

Table 1. Search strategies and keywords.

	Search Strategies
keywords	Advanced keyword search ((canine) AND (mandibular)) AND (impacted)
Databases	PubMed, Cochrane, Scopus, Web of Science

Initial screening was performed using the electronic databases PubMed, Scopus, Web of Science, and Cochrane (June 2022), with the Boolean indicators canine AND mandibular AND impacted. The titles and abstracts of scientific studies were assessed, and an initial screening was performed. Articles were restricted to randomized and non-randomized human clinical trials, prospective and retrospective studies, clinical case reports, and case series, and the full text was assessed for suitability for descriptive analysis.

2.1.2. Inclusion and Exclusion Criteria

The criteria required for inclusion (Table 2) in the qualitative synthesis were limited to studies including patients aged between 9 and 18 years with inclusion and/or transmigration of the mandibular canine, original prospective and retrospective studies on human subjects, studies including a clear description of the materials and techniques applied, and studies with surgical and orthodontic techniques.

Table 2. Inclusion and exclusion criteria.

Inclusion Criteria	Exclusion Criteria
English language	Non-English-language articles
Full text Human	Reviews
Research from 2017 to 2022	Letters to the editor
Studies of patients aged 9–18 years with inclusion and/or transmigration of the mandibular canine	Studies on patients with genetic syndromes
Original prospective and retrospective studies on human subjects	Studies on patients with severe facial malformations
Studies including a clear description of the materials and techniques applied	
Studies with surgical and orthodontic techniques	

The exclusion criteria (Table 2) were studies on patients with genetic syndromes and severe facial malformations, systematic literature reviews and letters to editors, and non-English-language articles.

2.1.3. Article Identification Procedure

The suitability assessment was conducted independently by three reviewers (C.V., G.L. and C.M.). In addition, a manual search was conducted to increase the pool of articles for full-text evaluation. Articles written in English that met the inclusion criteria were taken into account, while duplicates and excluded articles were categorized by stating the reasons for exclusion.

2.1.4. Study Evaluation

The article data were independently evaluated by the reviewers using a special electronic form designed according to the following categories: study model design, patient age, major symptoms, associated neoplasms or neoformations, treatment protocol, surgical technique, postoperative sequelae, tooth position, periodontal evaluation of included canines, number of subjects, and study results.

2.1.5. Risk-of-Bias Evaluation

The risk of bias was evaluated in accordance with the OHAT risk-of-bias tool for human and animals studies. The evaluation considered the following criteria: confounding bias, detection bias, confidence in the outcome, reporting bias, and other biases. The risk-of-bias findings were classified as adequate, unclear, or inadequate. The selected studies were categorized as having a low risk of bias with a minimum ratio of 4/5 positive parameters. Otherwise, the studies were classified as high-risk-of-bias articles.

3. Results

3.1. Study Selection and Characteristics

The electronic database and manual search output retrieved a total of 536 manuscripts (Scopus $n = 292$, PubMed $n = 121$, Web of Science $n = 109$, Cochrane $n = 14$); a total of 240 duplicates was removed. After initial screening, a total of 296 manuscripts was considered. Eligibility assessment was conducted on 46 articles, because 238 articles were off-topic, and the full text of 12 was not available. After reading the full texts, 11 articles were selected for qualitative synthesis. The PRISMA flowchart diagram is illustrated in Figure 2.

The review selection included a total of 19 cases of IMC. Seven articles described unilateral cases (TMC or IMC) [17–23] and four described bilateral cases (TMC and IMC) [24–27]. The mean age of the patients ranged from 11 to 18 years. The cases reported in the 11 articles concerned asymptomatic patients without dentigerous cysts. An orthodontic surgical approach was performed in all cases. Postoperative sequelae were often associated with mild healing symptoms. Gingival recession caused by bracket malposition on 4.3 was described in only one case [23]. Table 3 describes the studies' characteristics.

Table 3. Descriptive summary of item selection.

Authors	Journal	Study Design	Age	Symptoms	Treatment	Technique	Position	Final Periodontal Considerations
Kılıç et al. [19]	<i>Case Reports in Dentistry</i>	Case report	13.9	Asymptomatic	Orthodontic surgical exposure, elastic traction	Guided eruption in open technique	Transposed 4.3; impacted 3.3	The mandibular canines were brought to their own spaces, without any discomfort or side effects such as root resorption, alveolar destruction, or gingival recession, and they were properly positioned in the dental arch. Periodontal tissues were healthy during the treatment and retention periods.

Table 3. Cont.

Authors	Journal	Study Design	Age	Symptoms	Treatment	Technique	Position	Final Periodontal Considerations
Northway et al. [20]	<i>The Angle Orthodontist</i>	case report	11.7	Asymptomatic	Orthodontic surgical exposure, elastic traction	Guided eruption in closed technique	Transmigrated 4.3	At the final records appointment, the gingival height at the lower right canine was about 3 mm lower than that on the left side. However, there was a conspicuous improvement over the ensuing 7 years.
Vera Guerra et al. [21]	<i>Case Reports in Dentistry</i>	Case report	14	Asymptomatic	Orthodontic surgical exposure, elastic traction	Guided eruption in closed technique	Included 4.3; transmigrated 3.3	Both canines were successfully brought to a functional position within the dental arch and with a healthy periodontium.
Farcașiu et al. [22]	<i>Romanian Journal of Morphology and Embryology</i>	Case report	10	Asymptomatic	Orthodontic surgical exposure, elastic traction	Guided eruption in open technique	Transmigrated 3.3	The aspect of the gingiva in the anterior region was good, meaning that there was a good level of supporting bone, and that the surgical sutures were not tensed, allowing a normal healing rate.
Vergara-Villareal et al. [23]	<i>International Journal of Orthodontic Rehabilitation</i>	Case report	11	Asymptomatic	Orthodontic surgical exposure, elastic traction	Guided eruption in open technique	Included 4.3	Not reported.
Stabryła et al. [24]	<i>The Journal of the American Dental Association</i>	Retrospective study	15	Asymptomatic	Orthodontic surgical exposure, elastic traction	Guided eruption in closed technique; avulsion of transmigrated canines	Included and transmigrated 3.3 and 4.3	No adverse effects of orthodontic extrusions—such as severe root resorption of adjacent teeth, enamel demineralization, loss of pulpal vitality, or gingival recession—were observed in this sample.
Han et al. [14]	<i>Australasian Orthodontic Journal</i>	Case report	12	Asymptomatic	Orthodontic surgical exposure, elastic traction	Guided eruption in open technique	Included 3.3 and 4.3	The post-treatment CBCT scan showed that there was no buccal alveolar bone resorption around the mandibular canines after arch expansion, and that the canine roots were well aligned in the middle of the alveolar bone; good periodontal health around 4.3 and 3.3.

Table 3. Cont.

Authors	Journal	Study Design	Age	Symptoms	Treatment	Technique	Position	Final Periodontal Considerations
Nowzari et al. [25]	<i>JERD</i>	Pilot study	15	Asymptomatic	Orthodontic surgical exposure, elastic traction	Guided eruption in closed technique	Maxillary canines included; two mandibular canines included	Post-orthodontic treatment, the periodontal probing depth averaged 2.2 mm, and the zone of keratinized gingiva averaged 3.6 mm. No discernible radiographic bone loss or root resorption was noticed. Overall, gingival margins provided an esthetic appearance in all cases.
Topka et al. [26]	<i>Journal of Stomatology</i>	Case report	11.1	Asymptomatic	Orthodontic surgical exposure, metallic traction	Guided eruption in closed technique	Included 4.3	Case 1: The second complication—namely, root resorption—was evidenced in Case 2 where, due to the presence of gingival recession of tooth 4.3, the patient was monitored by a periodontologist, who proposed coverage of the recession with an autogenic transplant at the right age for the patient.
Taffarel et al. [27]	<i>Journal of Clinical and Diagnostic Research</i>	Case report	12	Asymptomatic	Orthodontic surgical exposure, elastic and metallic traction	Guided eruption in closed technique	Transmigrated 4.3	Strong appearance of the ridges and trabecular bone; no negative effects (such as root resorption or periodontal problems).
Jaisinghani et al. [28]	<i>Orthodontic Waves</i>	Case report	18	Asymptomatic	Orthodontic surgical exposure, elastic and metallic traction, and TADS	Guided eruption in closed technique	Transmigrated 4.3	Gingival recession on 4.3; not treated by the author as it was cosmetically negligible

3.2. Risk-of-Bias Assessment Findings

The analysis is presented in Figure 3 for a total of 11 included articles. A total of three articles showed a low risk of bias considering the heterogeneity of the model designs and methodologies. No randomized/blinded clinical trials were detected for further qualitative assessment and meta-analysis statistical evaluation.

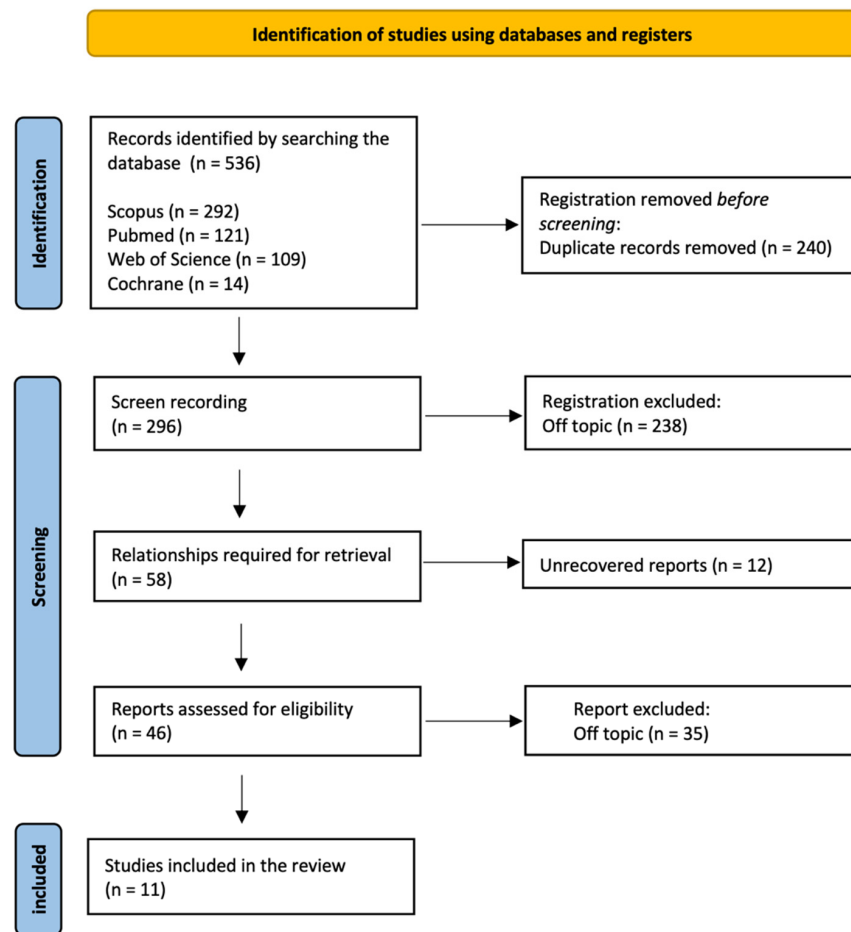


Figure 2. PRISMA flowchart diagram of the inclusion process.

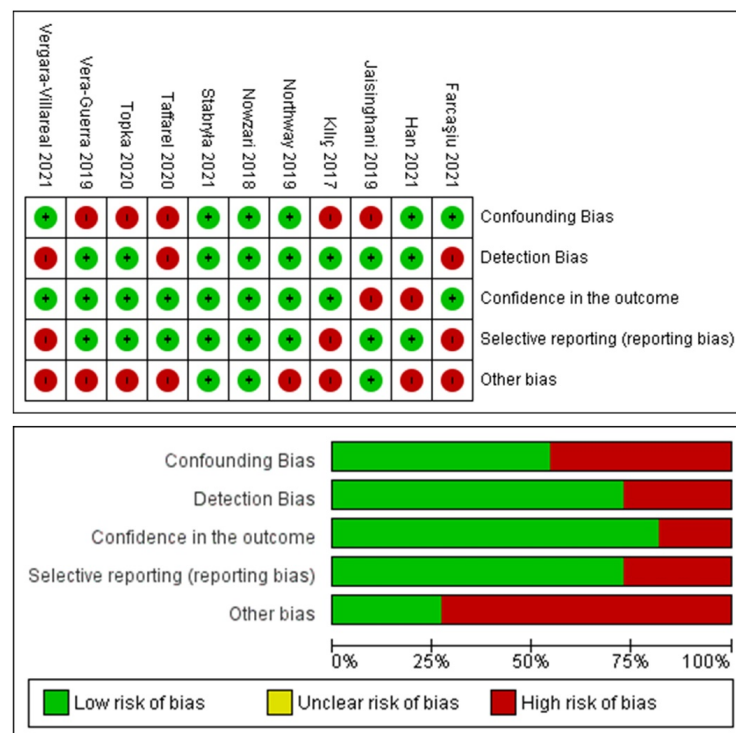


Figure 3. Graphs of the risk-of-bias assessment of the included studies.

4. Case Report

The patient was an 11.5-year-old child undergoing orthodontic treatment. He presented with mixed dentition, Angle Class I dental relationship of the permanent dentition with a 1 mm overjet, centered midlines, and slight crowding in both arches. All clinical documentation—consisting of impressions and study models (Figure 4), Rx OPT (Figure 5), lateral cranial Rx (Figure 6), and cephalometric analysis (Figure 7, Table 4)—was collected for case evaluation and subsequent treatment.

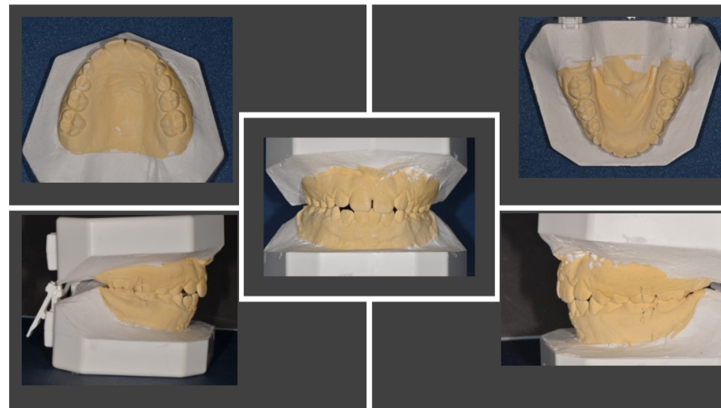


Figure 4. Study models before orthodontic therapy.

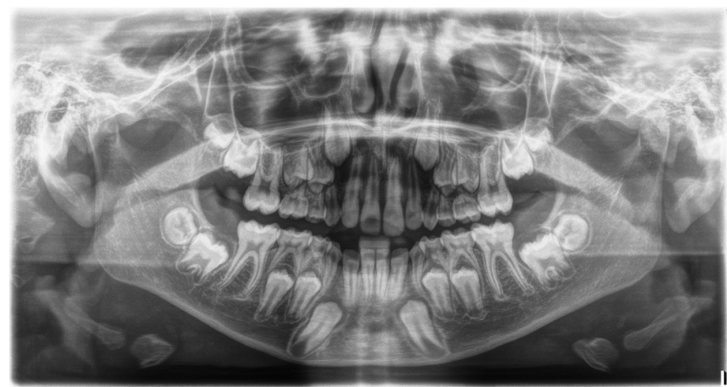


Figure 5. Rx OPT before orthodontic treatment.

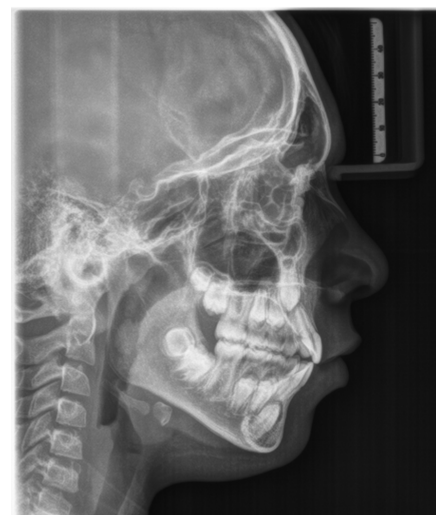

Figure 6. Lateral cranial radiograph.

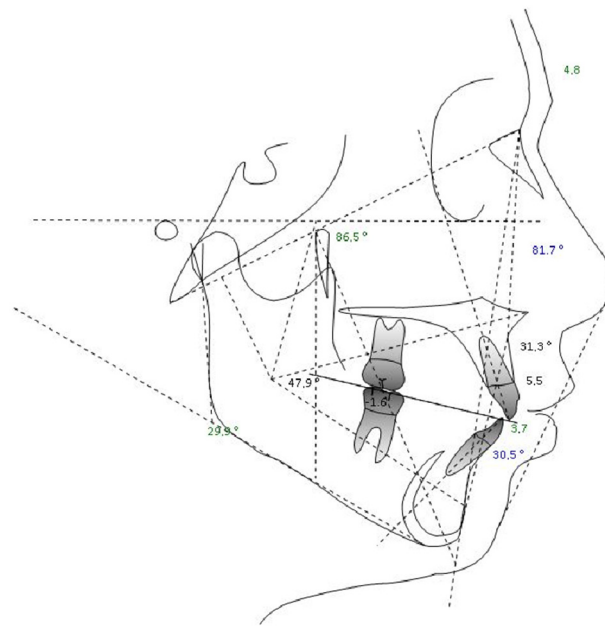


Figure 7. Cephalometric analysis.

Table 4. Cephalometric analysis results.

Dental Reports				
Measure	Value	Mean	Deviation	Measurement Analysis
Molar report (A6-B6) –1, N	–1.6	–3 ± 3	N	Class I dental
Overjet (B1-A1 Horz.)	1.8	2.5 ± 2.5	N	Normal
Overbite (B1-A1 Vert.)	0.2	2.5 ± 2.5	N	Normal
Inferior incisor extrusion (B1-Occl.)	0.5	1.25 ± 2	N	Normal
Angulo Interincisivo (A1-B1 angle)	118.2	132 ± 6	-XX	
G02—Skeletal Reports				
Convexity (A-NPog)	4.8	1 ± 2	X	Class II bone
Lower face height (ANS-Xi-Pm)	47.9°	47 ± 4	N	Facial meso
Dentoskeletal Ratios				
Upper molar position	12.1	17 ± 3	-X	Class III
Inferior incisor protrusion (B1-APog)	3.7	1 ± 2.3	X	Protrusion
Superior incisor protrusion (A1-APog)	5.5	3.5 ± 2.3	N	Normal
Lower incisor inclination	30.5°	22 ± 4	XX	
Upper incisor inclination	31.3°	28 ± 4	N	Normal
Occlusal plane inclination	19.9°	24.5 ± 4	-X	
Craniofacial Reports				
Facial depth (PoOr-NPog)	81.7°	88.5 ± 3	-XX	Facial dolic
Facial axis (BaN-PTGn)	86.5°	90 ± 3	-X	Facial dolic
With facial icity	68.4°	68 ± 3.5	N	Facial meso
Mandibular plane angle (GocMe-P)	29.9°	24.5 ± 4	X	Facial dolic
Jaw depth (PoOr-NA)	86.8°	90 ± 3	-X	Retrognathia
Palatal floor (PoOr-ANSPNS)	0.3°	1 ± 3.5	N	

After one year of interceptive therapy, a control Rx OPT was performed to assess the status of the tooth permutation (Figure 8).

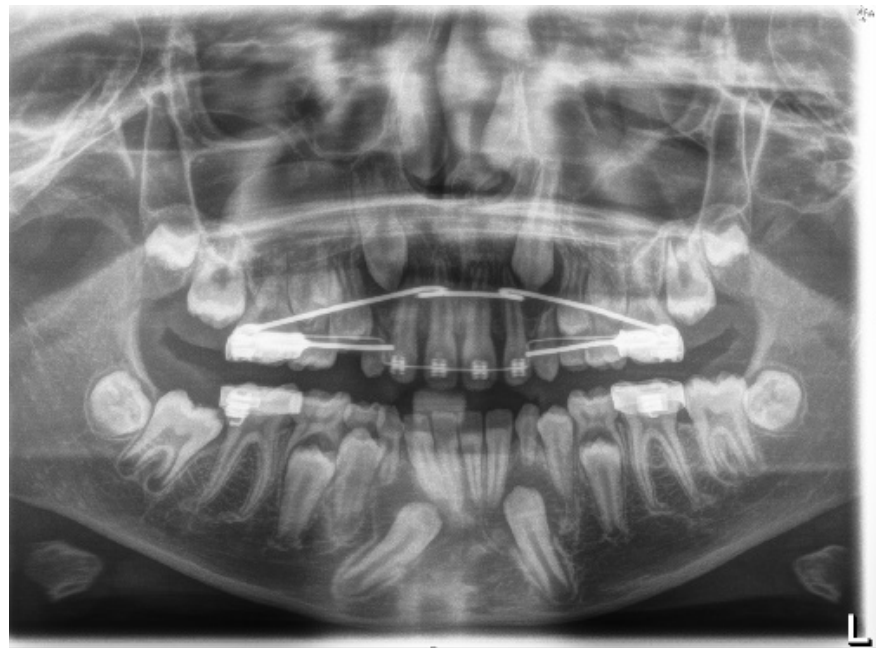
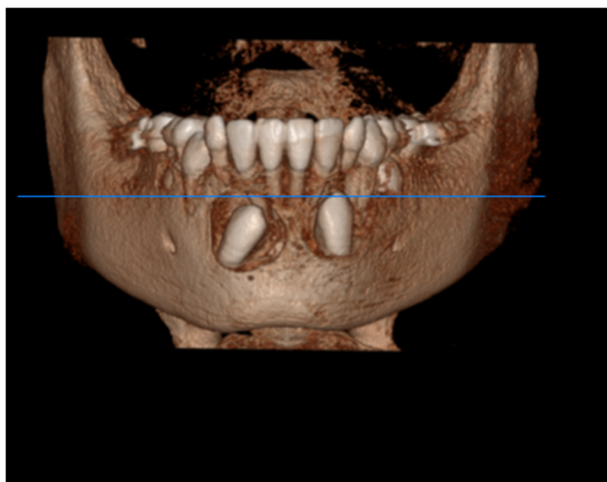


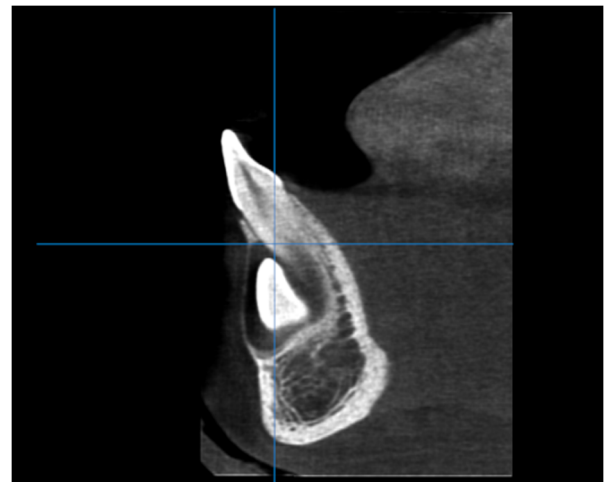
Figure 8. Rx OPT with inclusion of element 4.3.

The Rx OPT showed the intraosseous inclusion with mesio angulation of the 4.3 element. IMC was assessed according to Mupparapu's classification [5], which describes five types of transmigrated mandibular canine (Figure 1). The clinical case described in this article concerns type number 1.

CBCT was performed to assess the position of the IMC in relation to the surrounding anatomical structures (Figure 9).

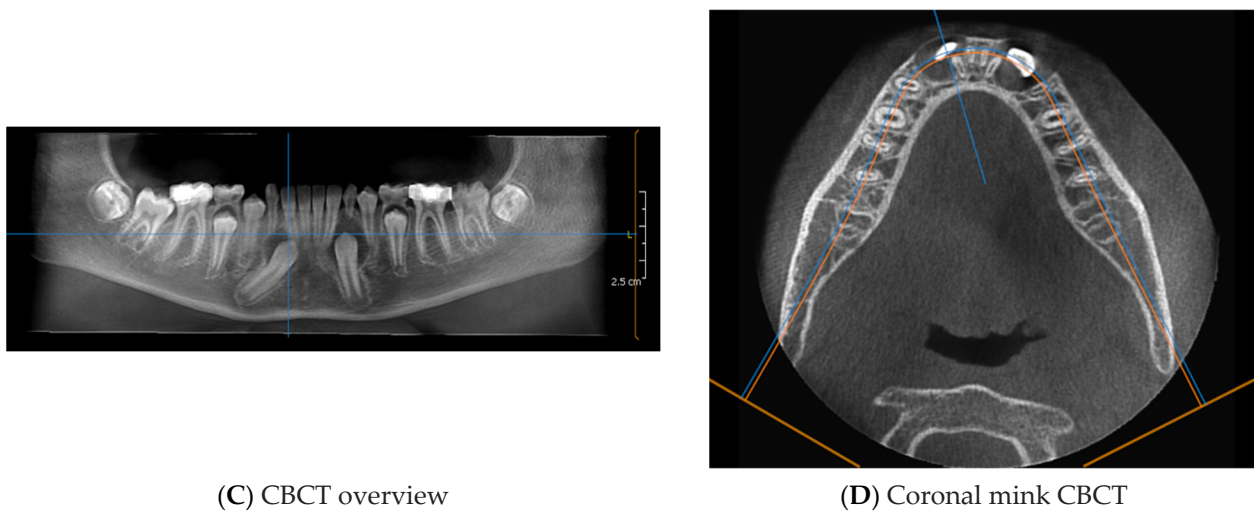


(A) CBCT front view



(B) CBCT sagittal view

Figure 9. Cont.



(C) CBCT overview

(D) Coronal mink CBCT

Figure 9. CBCT of the IMC ((A) + (B) + (C) + (D)).

The CBCT showed part of the crown of the IMC (4.3) in contact with the root apices of the right lower incisors. (4.1 and 4.2).

All of this diagnostic information allowed us to choose between the following treatment options:

- Interceptive treatment, including the extraction of a primary canine or the opening of an orthodontic space with fixed appliances [29];
- Orthodontic extrusion of 4.3 [26];
- Transalveolar transplantation of 4.3 [30];
- Avulsion of 4.3 [31].

The positional factors that influenced the decision to surgically remove or surgically expose the IMC were considered. These included the following:

1. Canine angle to the midline;
2. Horizontal position of the canine root apex;
3. Vertical height of the canine crown;
4. Canine overlap of adjacent tooth;
5. Buccal–lingual position of the canine.

After explaining the clinical situation and the possible therapeutic solutions to the parents and the young patient, it was decided, after obtaining the informed consent of the parents, to recover the included element (4.3) through a combined orthodontic–surgical approach. The treatment involved three phases, which are described below.

4.1. Phase 1: Initial Orthodontic Treatment

The first phase of the treatment involved orthodontic therapy aimed at preparing the anchorage teeth by aligning and levelling the arches. Once the maximum thickness of the wires was reached, the decision was made to surgically anchor the IMC.

4.2. Phase 2: Surgical Technique

After local anesthetic infiltration, an intrasulcular incision was made from 4.3 to 4.1, and then a vertical release incision (mesial to 4.1) was made to facilitate elevation and visibility of the flap. A full-thickness flap was elevated. Avulsion of the corresponding deciduous element was performed. The apical cortex of the alveolus was removed to reach the crown of the IMC. A bone tunnel was created through which the ligature was passed so that traction would be directed towards the center of the ridge (tunnel technique) [15].

Using an adhesion technique, an orthodontic bracket was bonded to 4.3 and connected to a metal ligature. The metal ligature was inserted along the previously created tunnel. The adhesion was finally tested by applying forced traction (of approximately 150 g). After

thorough washing of the surgical field, the mucoperiosteal flap was finally repositioned and sutured.

4.3. Orthodontic Traction

Orthodontic traction was achieved through the use of a metal ligature directly on the multiple brackets in the presence of a rigid full-thickness steel wire. The traction force was approximately 50–60 g, with activation of the wire every 15–20 days.

4.4. Phase 3: Final Orthodontic Treatment

After the recovery of the element included in the arch was achieved, orthodontic therapy continued with the final steps to finalize the case (Figure 10).

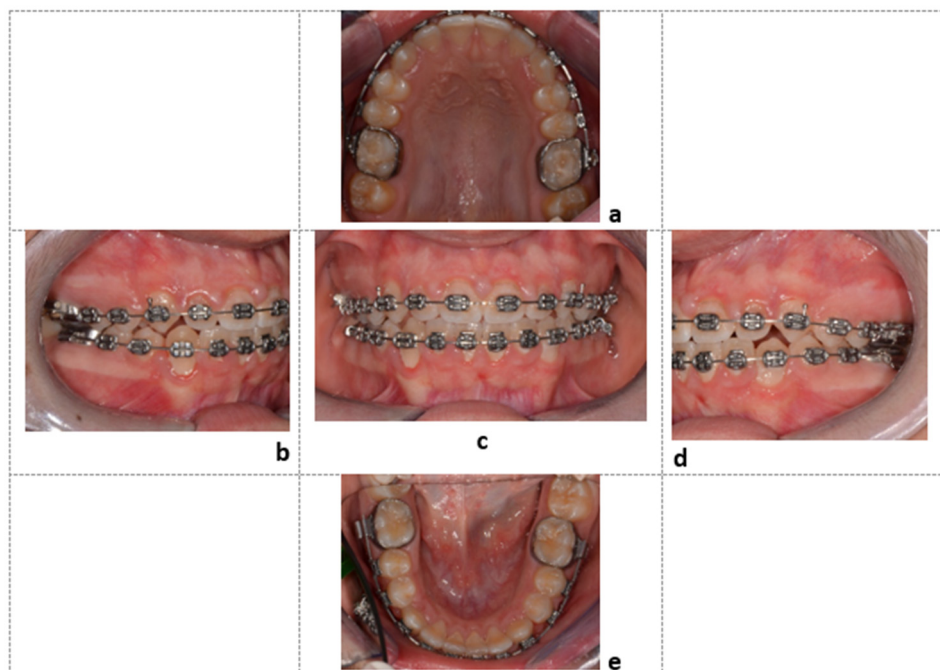


Figure 10. Final intraoral photos of the patient: Element 4.3, recovered in the center of the dental arch, observed from the upper occlusal view (a), right lateral view (b), frontal view (c), left lateral view (d), and lower occlusal view (e).

5. Discussion

The treatment of IMCs requires a multidisciplinary approach [27]. Just as spontaneous eruption occurs harmoniously and leads to tooth alignment in the presence of healthy periodontal tissues, the combined surgical–orthodontic treatment of an included element should simulate physiological eruption [28]. Therefore, the aim of orthodontic therapy is to guide the eruption of the tooth towards the center of the ridge, while surgical treatment should ensure that the dental and periodontal structures are respected to avoid damage at the end of therapy [19].

Regarding the treatment of IMCs and TMCs, several treatment options can be considered, including orthodontic traction, self-grafting, and surgical removal of the IMC. The strategy of surgically removing IMCs is the quickest and easiest. Although more difficult and complicated, orthodontic traction is the most effective strategy to restore ideal occlusion. Orthodontic mini-screws can be used as temporary anchorage devices to prevent the negative effects of anchorage loss [28]. From a therapeutic point of view, radiological diagnosis in late mixed dentition remains an important tool to detect incidents of mandibular canine inclusion. The clinical case presentation describes the surgical technique of IMC exposure and repositioning in the arch using a combined surgical–orthodontic treatment. Guided eruption techniques have several benefits in dentistry. They can be used for several

purposes, such as for tissue regeneration in either lingual [32] or conventional mechanics for impacted teeth [33]. There are two guided eruption techniques towards the center of the alveolar ridge: closed [34] and open [35,36]. In the first technique, an orthodontic bracket is attached to the tooth surface after a full-thickness flap is lifted, and the tooth and bracket are then entirely covered with tissue; meanwhile, the latter (open) method consists of apical repositioning of the full-thickness flap, leaving the element open [36–38]. The closed guided eruption technique was adopted in the clinical case described [20]. In the open guided eruption technique, an operculum is made on the IMC and an orthodontic traction is placed on it [20]. In both techniques, the principles of conservative surgery, adhesive technique, and controlled orthodontic traction are applied. In the cases selected in this review, one case with gingival recession was found [28]. In all cases there was periodontal success of the treated IMCs [19–27,39].

The reported clinical case was managed using the closed orthodontic eruption technique [15]. A mucoperiosteal flap was prepared with preservation of the interdental papillae, elevated to full thickness to allow minimal exposure of the included tooth for bracket adhesion. The minimal removal of cortical bone and pericoronal tissue, as well as the application of light forces during traction [40], also seems to explain the favorable periodontal outcome.

Some authors state that surgical exposure of the enamel–cement line predisposes patients to a greater risk of gingival recession and bone loss [41]. Finally, repositioning the flap in its original position maintains the entire portion of keratinized tissue, and reduces discomfort during healing [42].

Since the element in the bone inclusion was associated with the presence of the corresponding deciduous element in the arch, the “tunnel” technique was applied, as originally described by Crescini et al. in 1994 [15].

The extraction of the deciduous element creates a natural bone tunnel, and traction through this tunnel simulates a physiological eruption. The tooth is orthodontically pulled towards the center of the ridge, allowing the preservation of keratinized gingival tissue and subsequent periodontal health [34].

6. Conclusions

Although inclusion and transmigration of mandibular canines is a rare clinical condition, it is necessary to shed light on the most predictable treatment options to enable clinicians to carry out effective treatment protocols. According to the articles examined in our review, combined surgical–orthodontic treatment results in clinical success in the majority of cases, in terms of correcting the eruption defect, bringing the canine back into occlusion and into the physiological arch perimeter, and the health of the periodontal supporting tissue. To enable arch alignment of the tooth element while preserving periodontal integrity, the surgical–orthodontic traction must simulate the physiological eruption of the included tooth. All of the articles reviewed describe successful treatments for arch alignment, but periodontal success was not achieved in some of the cases described, due to bone ridge resorption, gingival recession, or root resorption; these are the main complications of surgical–orthodontic traction of the included elements, but the small percentage of cases in which they occurred allows this protocol to be defined as effective and predictable. More research is needed to understand the treatment outcomes of complex clinical cases, such as ankylosed elements.

Author Contributions: Conceptualization, A.D.I., V.C., F.P., F.I., A.M.I., D.D.V., G.D. and B.R.; methodology, A.N., I.F., M.C., G.L., F.V., S.C. (Sabino Ceci), G.M., A.P. (Andrea Palermo), A.M., C.L. and B.R.; software, A.P. (Assunta Patano), F.L., B.R. and G.D.; validation, F.I., A.P. (Assunta Patano), B.R., D.D.V., G.D., A.D.I., A.M.I. and A.S.; formal analysis, V.C., F.L., B.R., D.D.V. and A.D.I.; investigation, A.M.C., G.D., A.D.I., F.L., A.M.I., B.R., A.S. and F.I.; resources, A.M.I., G.D., B.R., A.D.I., F.I. and G.M.; data curation, G.D., I.F., F.L., A.N., B.R., A.M., F.V., M.C., S.C. (Stefania Costa), V.C., G.L., F.P., F.I. and D.D.V.; writing—original draft preparation, A.D.I., A.M.I., G.D., V.C., B.R., A.S. and F.I.; writing—review and editing, V.C., B.R., F.I., D.D.V., G.M. and G.D.; visualization, F.I., B.R. and

A.S.; supervision, B.R., D.D.V., F.I., A.D.I. and A.S.; project administration, F.I., G.D., D.D.V. and B.R. All authors have read and agreed to the published version of the manuscript.

Funding: This research received no external funding.

Institutional Review Board Statement: This clinical study was based at the University of Bari (Italy), in full compliance with ethical principles, including the Declaration of Helsinki of the World Medical Association, and the additional requirements of Italian law. In addition, the University of Bari, Italy, classified the study as exempt from ethical review, as it carries only negligible risks and involves the use of existing data that contain only non-identifiable data on humans. The patient in the case report signed a written informed consent form.

Informed Consent Statement: Informed consent was obtained from the subject involved in the study. Written informed consent was obtained from the patient to publish this document.

Data Availability Statement: All experimental data supporting the results of this study are available from the corresponding author upon request.

Conflicts of Interest: The authors declare no conflict of interest.

Abbreviations

IMC	Included mandibular canine
TMC	Transmigrated mandibular canine
IMXC	Included maxillary canine
OPT	Orthopantomography
PRISMA	Preferred Reporting Items for Systematic Reviews and Meta-Analyses
CBCT	Cone-beam computed tomography
4.3	Lower mandibular canine
4.1	Lower-right central incisor
4.2	Lower-right lateral incisor

References

1. Cavuoti, S.; Matarese, G.; Isola, G.; Abdolreza, J.; Femiano, F.; Perillo, L. Combined Orthodontic-Surgical Management of a Transmigrated Mandibular Canine. *Angle Orthod.* **2015**, *86*, 681–691. [[CrossRef](#)] [[PubMed](#)]
2. Alhammedi, M.; Asiri, H.; Almashraqi, A. Incidence, Severity and Orthodontic Treatment Difficulty Index of Impacted Canines in Saudi Population. *J. Clin. Exp. Dent.* **2018**, *10*, e327–e334. [[CrossRef](#)] [[PubMed](#)]
3. Gündüz, K.; Çelenk, P. The Incidence of Impacted Transmigrant Canines: A Retrospective Study. *Oral Radiol.* **2010**, *26*, 77–81. [[CrossRef](#)]
4. Inchingolo, A.D.; Patano, A.; Coloccia, G.; Ceci, S.; Inchingolo, A.M.; Marinelli, G.; Malcangi, G.; Montenegro, V.; Laudadio, C.; Pede, C.D.; et al. The Efficacy of a New AMCOP® Elastodontic Protocol for Orthodontic Interceptive Treatment: A Case Series and Literature Overview. *Int. J. Environ. Res. Public Health* **2022**, *19*, 988. [[CrossRef](#)] [[PubMed](#)]
5. Mupparapu, M. Patterns of Intra-Osseous Transmigration and Ectopic Eruption of Mandibular Canines: Review of Literature and Report of Nine Additional Cases. *Dentomaxillofacial Radiol.* **2002**, *31*, 355–360. [[CrossRef](#)]
6. Majumdar, S.K.; Hossain, M.A.; De, N.; Chadda, D.; Bachhar, M.K.; Mishra, S. Effect of Diagnosis by Two-Dimensional Radiography Versus CBCT on Surgical Aspects of Transmigrated Impacted Mandibular Canines. *J. Maxillofac. Oral Surg.* **2020**, *19*, 461–467. [[CrossRef](#)]
7. Laudadio, C.; Inchingolo, A.D.; Malcangi, G.; Limongelli, L.; Marinelli, G.; Coloccia, G.; Montenegro, V.; Patano, A.; Inchingolo, F.; Bordea, I.R.; et al. Management of Anterior Open-Bite in the Deciduous, Mixed and Permanent Dentition Stage: A Descriptive Review. *J. Biol. Regul. Homeost. Agents* **2021**, *35*, 271–281. [[CrossRef](#)]
8. Montenegro, V.; Inchingolo, A.D.; Malcangi, G.; Limongelli, L.; Marinelli, G.; Coloccia, G.; Laudadio, C.; Patano, A.; Inchingolo, F.; Bordea, I.R.; et al. Compliance of Children with Removable Functional Appliance with Microchip Integrated during Covid-19 Pandemic: A Systematic Review. *J. Biol. Regul. Homeost. Agents* **2021**, *35*, 365–377. [[CrossRef](#)]
9. Cirulli, N.; Ballini, A.; Cantore, S.; Farronato, D.; Inchingolo, F.; Dipalma, G.; Gatto, M.R.; Alessandri Bonetti, G. Mixed Dentition Space Analysis of a Southern Italian Population: New Regression Equations for Unerupted Teeth. *J. Biol. Regul. Homeost. Agents* **2015**, *29*, 515–520.
10. Inchingolo, A.D.; Ceci, S.; Patano, A.; Inchingolo, A.M.; Montenegro, V.; Di Pede, C.; Malcangi, G.; Marinelli, G.; Coloccia, G.; Garibaldi, M.; et al. Elastodontic Therapy of Hyperdivergent Class II Patients Using AMCOP® Devices: A Retrospective Study. *Appl. Sci.* **2022**, *12*, 3259. [[CrossRef](#)]
11. Inchingolo, A.D.; Patano, A.; Coloccia, G.; Ceci, S.; Inchingolo, A.M.; Marinelli, G.; Malcangi, G.; Montenegro, V.; Laudadio, C.; Palmieri, G.; et al. Genetic Pattern, Orthodontic and Surgical Management of Multiple Supplementary Impacted Teeth in a Rare, Cleidocranial Dysplasia Patient: A Case Report. *Medicina* **2021**, *57*, 1350. [[CrossRef](#)] [[PubMed](#)]

12. Bertl, M.H.; Frey, C.; Bertl, K.; Giannis, K.; Gahleitner, A.; Strbac, G.D. Impacted and Transmigrated Mandibular Canines: An Analysis of 3D Radiographic Imaging Data. *Clin. Oral Investig.* **2018**, *22*, 2389–2399. [[CrossRef](#)] [[PubMed](#)]
13. Azeem, M.; Afzal, A.; Ahmed, Z.; Ali, M.M.; Haq, A.U.; Hamid, W.U. Investigation of Transmigrated Mandibular Canines. *Dent. Press J. Orthod.* **2019**, *24*, 65. [[CrossRef](#)] [[PubMed](#)]
14. Cakir Karabas, H.; Ozcan, I.; Erturk, A.F.; Guray, B.; Unsal, G.; Senel, S.N. Cone-Beam Computed Tomography Evaluation of Impacted and Transmigrated Mandibular Canines: A Retrospective Study. *Oral Radiol.* **2021**, *37*, 403–411. [[CrossRef](#)] [[PubMed](#)]
15. Crescini, A.; Baccetti, T.; Rotundo, R.; Mancini, E.A.; Prato, G.P. Tunnel Technique for the Treatment of Impacted Mandibular Canines. *Int. J. Periodontics Restor. Dent.* **2009**, *29*, 213–218.
16. Plaza, S.P. Orthodontic Traction of a Transmigrated Mandibular Canine Using Mini-Implant: A Case Report and Review. *J. Orthod.* **2016**, *43*, 314–321. [[CrossRef](#)] [[PubMed](#)]
17. Dalessandri, D.; Parrini, S.; Rubiano, R.; Gallone, D.; Migliorati, M. Impacted and Transmigrant Mandibular Canines Incidence, Aetiology, and Treatment: A Systematic Review. *Eur. J. Orthod.* **2017**, *39*, 161–169. [[CrossRef](#)]
18. Page, M.J.; McKenzie, J.E.; Bossuyt, P.M.; Boutron, I.; Hoffmann, T.C.; Mulrow, C.D.; Shamseer, L.; Tetzlaff, J.M.; Akl, E.A.; Brennan, S.E.; et al. The PRISMA 2020 Statement: An Updated Guideline for Reporting Systematic Reviews. *PLoS Med.* **2021**, *18*, e1003583. [[CrossRef](#)]
19. Kılıç, N.; Oktay, H. Orthodontic Intervention to Impacted and Transposed Lower Canines. *Case Rep. Dent.* **2017**, *2017*, 4105713. [[CrossRef](#)]
20. Northway, W. Orthodontic Management of a Dental Anomaly Pattern (DAP) Including Mandibular Canine Transmigration: A Case Report: A Challenging Treatment but Worth It! *Angle Orthod.* **2019**, *89*, 149–162. [[CrossRef](#)]
21. Vera-Guerra, J.A.; Herrera-Atoche, J.R.; Colomé-Ruiz, G.E. Orthodontic Treatment of Bilateral Impacted Mandibular Canines and a Mupparapu Type 2 Transmigration. *Case Rep. Dent.* **2019**, *2019*, 7638959. [[CrossRef](#)] [[PubMed](#)]
22. Farcașiu, C.; Dinescu, M.I.; Tărlungeanu, D.I.; Bataiosu, M.; Daguci, C.; Daguci, L.; Dina, M.N.; Andrei, O.-C. A Rare Case of Transmigrated Mandibular Canine and Combined Orthodontic–Surgical Management. *Rom. J. Morphol. Embryol.* **2022**, *62*, 625–631. [[CrossRef](#)] [[PubMed](#)]
23. Vergara-Villareal, P.; Del Castillo, K.; Ramírez-Ossa, D.; Barbosa-Liz, D. An Innovative Therapeutic Alternative for Correcting the Direction of Eruption of a Lower Mandibular Cuspid: A Mixed Dentition Case Report. *Int. J. Orthod. Rehabil.* **2021**, *12*, 79. [[CrossRef](#)]
24. Stabryła, J.; Plakwicz, P.; Kukuła, K.; Zadurska, M.; Czochrowska, E.M. Comparisons of Different Treatment Methods and Their Outcomes for Impacted Maxillary and Mandibular Canines: A Retrospective Study. *J. Am. Dent. Assoc.* **2021**, *152*, 919–926. [[CrossRef](#)]
25. Nowzari, H.; Rodriguez, A.E. Impacted Teeth: Closed Flap Surgery. *J. Esthet. Restor. Dent.* **2019**, *31*, 233–239. [[CrossRef](#)]
26. Topka, A.; Racka-Pilszak, B.; Wojtaszek-Słomińska, A.; Orzelska-Blomberg, M. Surgical-Orthodontic Treatment of Impacted Permanent Canines in the Mandible: Two Case Reports. *Jstoma* **2020**, *72*, 282–290. [[CrossRef](#)]
27. Taffarel, I.A.; Taffarel, I.P.; Gasparello, G.G.; Pithon, M.M.; Tanaka, O.M. Transmigrated Mandibular Canine Guided into Its Normal Position. *J. Clin. Diagn. Res.* **2020**, *14*, ZD01–ZD04. [[CrossRef](#)]
28. Jaisinghani, A.P.; Pradhan, T.; Keluskar, K.M.; Takane, V. Treatment of a Transmigrated and an Impacted Mandibular Canine along with Missing Maxillary Central Incisor: A Case Report. *Orthod. Waves* **2019**, *78*, 84–92. [[CrossRef](#)]
29. Hamdan, H.A.; Grünheid, T.; Larson, B.E. Effect of Orthodontic Treatment with Preadjusted Edgewise Appliances on the Buccolingual Inclination of Mandibular Canines: A CBCT Study. *Orthod. Craniofac. Res.* **2015**, *18*, 156–164. [[CrossRef](#)]
30. Krasny, M.; Krasny, K.; Wojtowicz, A. En Bloc Autotransplantation of Retained Canine in the Mandible: A Case Presentation. *Int. J. Periodontics Restor. Dent.* **2020**, *40*, 403–407. [[CrossRef](#)]
31. Aras, M.; Halicioğlu, K.; Yavuz, M.; Caglaroglu, M. Evaluation of Surgical-Orthodontic Treatments on Impacted Mandibular Canines. *Med. Oral* **2011**, e925–e928. [[CrossRef](#)]
32. Paolone, M.G.; Kaitsas, R.; Paolone, G.; Kaitsas, V. Lingual Orthodontics and Forced Eruption: A Means for Osseous and Tissue Regeneration. *Prog. Orthod.* **2008**, *9*, 46–57. [[PubMed](#)]
33. Kaitsas, R.; Paolone, M.G.; Paolone, G. Guided Orthodontic Regeneration: A Tool to Enhance Conventional Regenerative Techniques in Implant Surgery. *Int. Orthod.* **2015**, *13*, 539–554. [[CrossRef](#)] [[PubMed](#)]
34. Crescini, A.; Nieri, M.; Buti, J.; Baccetti, T.; Mauro, S.; Pini Prato, G.P. Short- and Long-Term Periodontal Evaluation of Impacted Canines Treated with a Closed Surgical? Orthodontic Approach. *J. Clin. Periodontol.* **2007**, *34*, 232–242. [[CrossRef](#)] [[PubMed](#)]
35. Chaushu, S.; Becker, A.; Zeltser, R.; Branski, S.; Vasker, N.; Chaushu, G. Patients Perception of Recovery after Exposure of Impacted Teeth: A Comparison of Closed- versus Open-Eruption Techniques. *J. Oral Maxillofac. Surg.* **2005**, *63*, 323–329. [[CrossRef](#)]
36. Malcangi, G.; Inchingolo, A.D.; Patano, A.; Coloccia, G.; Ceci, S.; Garibaldi, M.; Inchingolo, A.M.; Piras, F.; Cardarelli, F.; Settanni, V.; et al. Impacted Central Incisors in the Upper Jaw in an Adolescent Patient: Orthodontic-Surgical Treatment—A Case Report. *Appl. Sci.* **2022**, *12*, 2657. [[CrossRef](#)]
37. Özer, M.; Şener, I.; Bayram, M. Bilaterally Impacted Maxillary Central Incisors: Surgical Exposure and Orthodontic Treatment: A Case Report. *J. Contemp. Dent. Pract.* **2006**, *7*, 98–105. [[CrossRef](#)]
38. Chaushu, S.; Zilberman, Y.; Becker, A. Maxillary Incisor Impaction and Its Relationship to Canine Displacement. *Am. J. Orthod. Dentofac. Orthop.* **2003**, *124*, 144–150, discussion 150. [[CrossRef](#)]
39. Han, L.; Mei, L.; Zhang, C.; Wu, T.; Wang, C. Correction of Class II Division 2 with Crowding and Bilateral Fully Transposed Impacted Mandibular Canines. *Australas. Orthod. J.* **2022**, *38*, 29–40. [[CrossRef](#)]

40. Bishara, S.E.; Ortho, D. Impacted Maxillary Canines: A Review. *Am. J. Orthod. Dentofac. Orthop.* **1992**, *13*, 159–171. [[CrossRef](#)]
41. Boyd, R.L. Clinical Assessment of Injuries in Orthodontic Movement of Impacted Teeth. II. Surgical Recommendations. *Am. J. Orthod.* **1984**, *86*, 407–418. [[CrossRef](#)]
42. Vermette, M.E.; Kokich, V.G.; Kennedy, D.B. Uncovering Labially Impacted Teeth: Apically Positioned Flap and Closed-Eruption Techniques. *Angle Orthod.* **1995**, *65*, 23–32, discussion 33. [[CrossRef](#)] [[PubMed](#)]